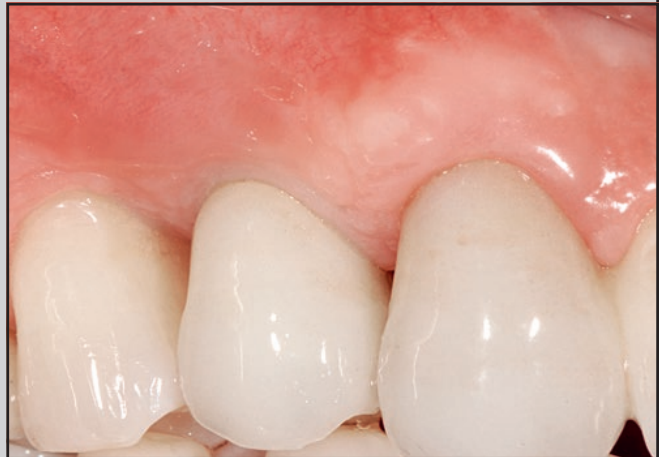
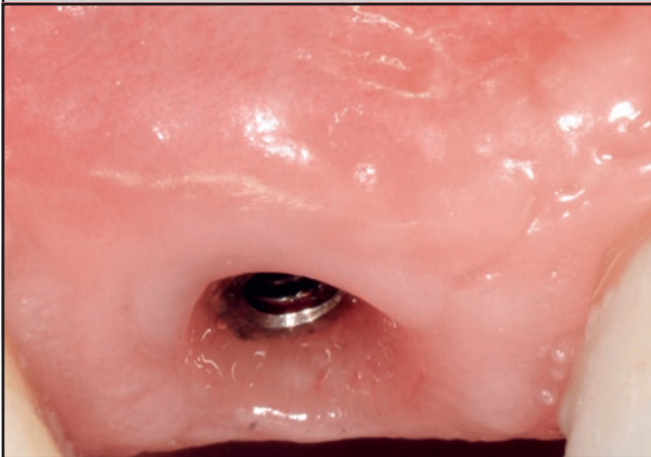
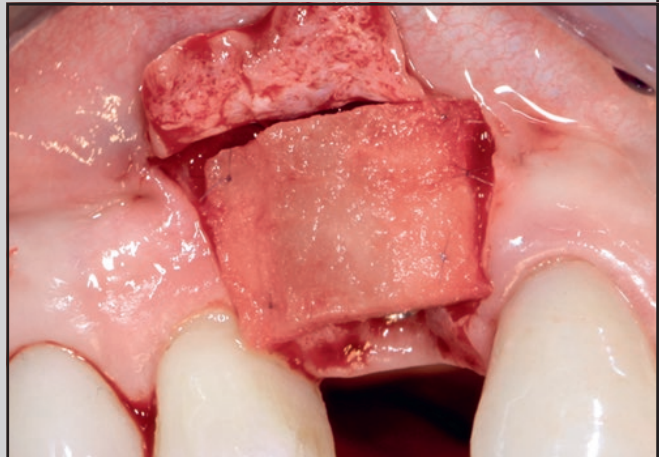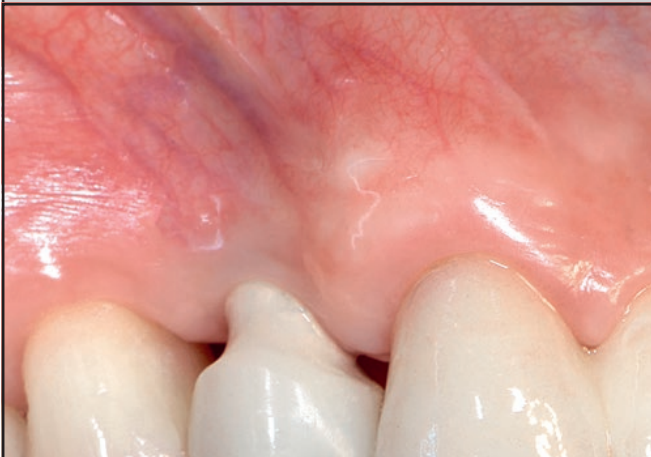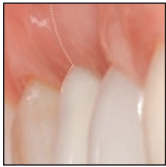# Porcine-Derived Acellular Dermal Matrix for Buccal Soft Tissue Augmentation at Single Implant Sites: A 1-Year Follow-up Case Series



Martina Stefanini, DDS, PhD<sup>1</sup>  
 Alexandra Rendon, DDS<sup>1</sup>  
 Giovanni Zucchelli, DDS, PhD<sup>1</sup>

*Soft tissue augmentation procedures are crucial to obtain a successful outcome in implant therapy. The aim of this case series was to describe the 1-year clinical outcomes of a porcine-derived acellular dermal matrix for buccal mucosal thickness augmentation at osseointegrated single implants with facial peri-implant soft tissue deficiencies. Ten patients were included and treated with a prosthetic and surgical approach that combined a coronally advanced flap and a dermal matrix. Results showed the possibility to obtain an increase in buccal soft tissue thickness of  $1.2 \pm 0.18$  mm at single implant sites in the esthetic area. Int J Periodontics Restorative Dent 2020;40:121–128. doi: 10.11607/prd.4477*

Replacing missing teeth with dental implants can be considered a standard of care in clinical scenarios of single missing teeth due to elevated implant survival rates (mean: 98%; range: 95% to 100%).<sup>1</sup> However, the success of an implant is dictated by stable osseointegration as well as several other factors, such as the ability of the implant-supported restoration to blend harmoniously into the surrounding dentition and the long-term health of the implant as a result of stable peri-implant hard and soft tissue dimensions.<sup>2</sup>

There is no current consensus regarding the need for keratinized mucosa or a minimum volume of peri-implant soft tissue that will guarantee prevention of peri-implant disease. However, recent publications provide guidelines for decision-making whenever the clinician must assess the need for volume augmentation of peri-implant soft tissues, the main clinical indications being: prevention of mucosal recessions, compensation of volume deficiencies, and facilitation of tissue adaptation for functional and/or esthetic purposes.<sup>3</sup> From an esthetic point of view, several studies have demonstrated that 2 mm of peri-implant mucosal thickness seems to be a threshold value for detecting color differences relating to underlying implant-restorative components, and with a 3-mm or greater thickness,

<sup>1</sup>Department of Biomedical and Neuromotor Sciences, Bologna University, Bologna, Italy.

Correspondence to: Dr Martina Stefanini, Department of Biomedical and Neuromotor Sciences, Bologna University, Via San Vitale 59, 40125 Bologna, Italy.  
 Email: martinastefanini3@gmail.com

Submitted May 23, 2019; accepted August 20, 2019.  
 ©2020 by Quintessence Publishing Co Inc.

no color changes are distinguishable by the human eye.<sup>4,5</sup> From a biologic point of view, the most up-to-date systematic review has concluded that soft tissue grafting procedures for gain of mucosal thickness result in significantly less peri-implant marginal bone loss over time.<sup>2</sup> A supracrestal soft tissue thickness of > 2 mm provides space for re-establishment of the biologic width around the implant-abutment interface, resulting in less peri-implant marginal bone remodeling and more stable bone levels thereafter.<sup>6,7</sup>

As confirmed by a recent consensus<sup>3</sup> in which the implementation of connective tissue grafting procedures is advised for augmentation of soft tissue thickness around implant sites displaying volume deficiencies, autogenous grafting remains the treatment of choice.<sup>8-10</sup> Nevertheless, it has been studied that involving an intraoral donor site may increase patient discomfort due to the additional surgical site, longer operating times, and/or associated healing complications.<sup>10-14</sup>

Soft tissue augmentation in terms of volume gain has not been predictably achieved yet with the use of several soft tissue substitutes,<sup>15</sup> and there are few clinical studies that have attempted to use the latter for treatment of soft tissue volume deficiencies at implant sites reporting long-term stability of the results.<sup>10,16-18</sup>

The aim of this case series was to describe the 1-year clinical outcomes of a porcine-derived acellular dermal matrix (PADM; Mucoderm, Botiss Biomaterials) for buccal mucosal thickness augmen-

tation at osseointegrated single implants with facial peri-implant soft tissue deficiencies.

## Materials and Methods

### *Study Design and Patient Selection*

Ten patients, each presenting one osseointegrated implant in the esthetic area (from second premolar to second contralateral premolar) with a buccal soft tissue deficiency (Class 1<sup>19</sup>), were selected. Their chief complaint was the unesthetic appearance of the treated area and/or discomfort caused by food impaction attributed to the inadequate emergence profile of the implant-supported restoration.

After agreeing to participate in this study, patients gave their written informed consent. All participants met the following inclusion criteria: (1) age > 18 years, (2) periodontally and systemically healthy, (3) replacement of one tooth in the esthetic area with a single implant that presented a buccal soft tissue deficiency after restoration (Class 1<sup>19</sup>), (4) no buccal sounding indicating implant thread exposure, (5) absence of peri-implantitis signs, (6) no interproximal attachment loss on teeth neighboring the implant, (7) no contraindications for periodontal surgery and not taking medications known to interfere with periodontal and peri-implant tissue health or healing, (8) smoking < 10 cigarettes a day, and (9) no previous soft tissue augmentation procedures at the experimental site.

The study protocol involved a screening appointment to verify eligibility of the patients, followed by initial therapy to establish optimal plaque control and gingival/mucosal health conditions. Clinical measurements were taken at baseline and 1 year after final restoration.

### *Clinical Parameters/Measurements*

The following clinical measurements were taken 2 weeks before surgery (baseline) and 1 year after final restoration:

- Height of keratinized tissue (KTH): measured from the soft tissue margin to the mucogingival junction (identified by means of Lugol staining).
- Soft tissue thickness (STT): determined 1.5 mm apical to the soft tissue margin with a short anesthesia needle and a 3-mm-diameter silicone stop. The needle was inserted into the soft tissues, perpendicular to the mucosal surface, with light pressure until a hard surface was met. The silicone stop was then placed in tight contact with the soft tissue surface, with its coronal border resting at the soft tissue margin. As the needle was located in the center of the silicone disk, measurement of STT was performed 1.5 mm apical from the soft tissue margin. Once in the correct position, the disk was fixed with a drop of cyanoacrylate adhesive; after careful

removal of the needle, penetration depth was measured with a digital caliper accurate to the nearest 0.1 mm.<sup>11,20–22</sup> All measurements (except STT) were performed by means of a manual probe and were rounded up to the nearest 0.5 mm.

- Probing depth (PD): measured buccally from the soft tissue margin to the bottom of peri-implant sulcus.
- Bleeding on probing (BoP): yes/no at 6 points per implant.
- Plaque Index (PI): yes/no at 6 points per implant.

#### *Initial Therapy/Provisional Prosthetic Phase*

The existing implant crowns on the treatment sites were removed, and a narrow provisional screw-retained crown was placed for 2 months in order to allow an increase in the interproximal space between the crown and the adjacent teeth. Surgeries were only performed after said space was filled with mature soft tissues that could serve as anchorage for the dermal matrix and also provide vascular supply for the surgical papillae of the covering flap.

#### *Surgical Technique*

All surgical procedures were performed by a single expert periodontist (G.Z.) with more than 10 years of experience in periodontal plastic surgery and implant dentistry. All sites were treated with a bilaminar

technique consisting of a coronally advanced flap (CAF) and PADM.<sup>23,24</sup>

A split-full-split-thickness buccal flap was elevated, taking care to eliminate all muscle insertions to allow its coronal advancement. The anatomical papillae were deepithelialized buccally and occlusally, creating connective tissue beds mesial and distal to the implant. Matrix dimensions were defined with the following rationale: mesiodistal length was 6 mm greater than the width of the implant platform, and the apico-coronal dimension was calculated from the level of the desired future gingival margin up to 3 mm covering the buccal bone crest. The matrix was positioned covering the implant-crown interface and secured at the base of each anatomical papilla, and at the apical portion if needed, with simple interrupted sutures (PGA 7-0, Marlin). The flap was repositioned to completely cover the matrix without tension and was fixed with simple interrupted sutures along the vertical releasing incisions and with a sling suture coronally. At the end of the surgery, the provisional crown was further reduced at the transmucosal portion to avoid contact with the soft tissues.

#### *Postsurgical Infection Control*

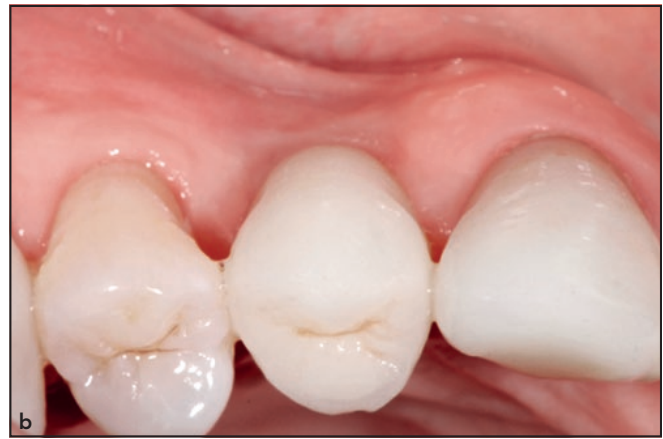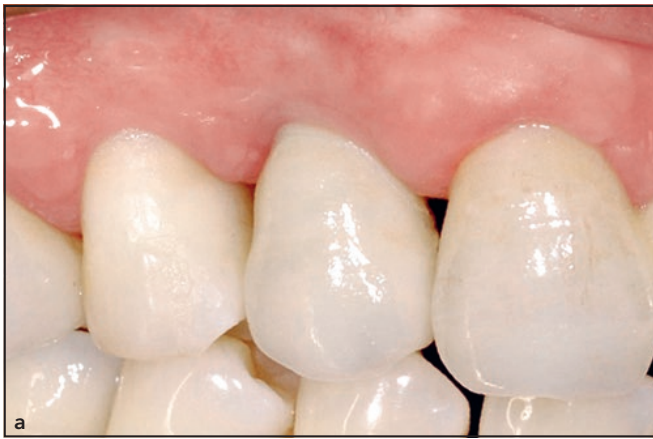Patients were indicated not to perform mechanical tooth cleaning at the surgical site, but to perform chemical plaque control instead with the use of 0.12% chlorhexidine mouth rinse (three times a day for 1 minute) during the first 2 weeks.

After said period, the sutures were removed and patients were instructed to brush using an ultra-soft postsurgical toothbrush with a coronally directed roll technique for the subsequent month. The next month, patients were told to change to a super-soft toothbrush (roll technique) while using the chlorhexidine rinse twice a day. Afterwards, patients would use a soft toothbrush and rinse with chlorhexidine once a day for another month. At the end of this phase, chlorhexidine was discontinued and full mechanical interproximal cleaning in the surgically treated area was reinstated. After suture removal, patients were recalled for professional prophylaxis every month during the first 2 months and, subsequently, every 3 months until the final evaluation at 1 year. The described treatment procedure is illustrated in Figs 1 to 6.

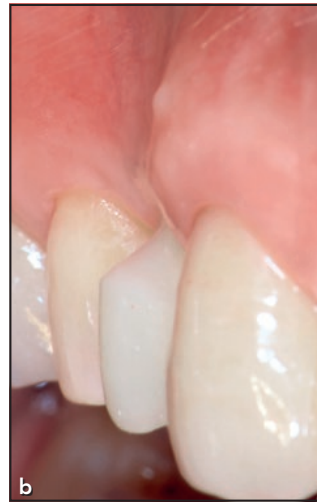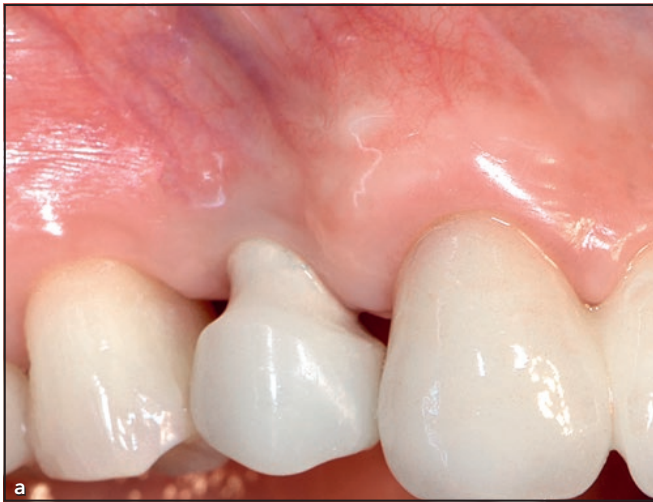## **Results**

The study population consisted of 10 subjects, of which 6 were female. The mean group age was 48.1 years of age (minimum: 36 years; maximum: 66 years). Seven implants were treated in the maxilla and 3 in the mandible; healing patterns did not seem to differ in relation to arch.

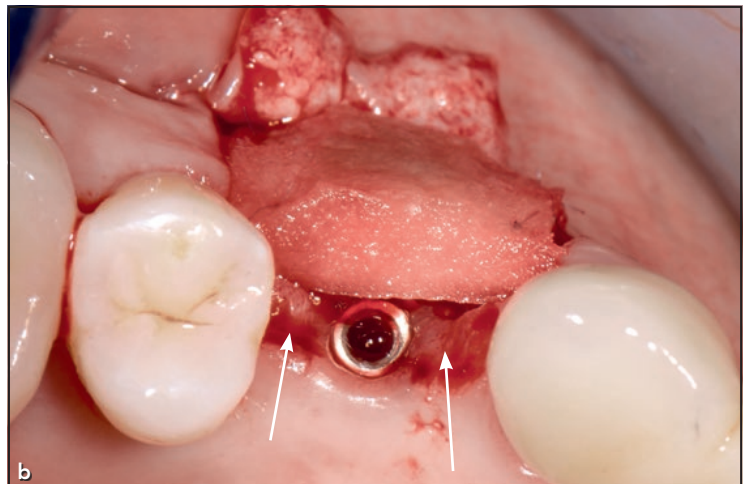
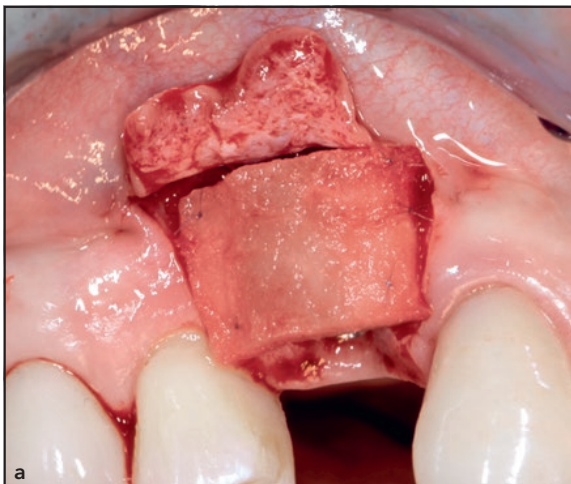
Following the initial oral hygiene phase and at the posttreatment examinations, all subjects showed a full-mouth plaque score and bleeding score of < 15% each, indicating good standard of supra-gingival plaque control during the study period.



**Fig 1** Baseline (a) buccal and (b) occlusal situation showing a Class 1 buccal peri-implant soft tissue deficiency.

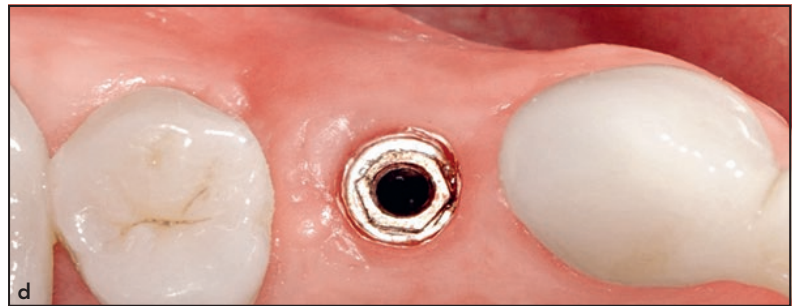
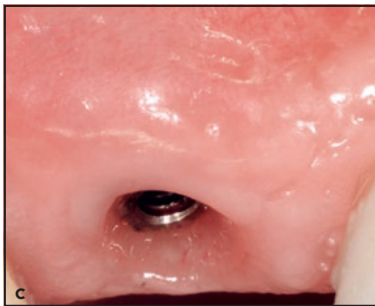
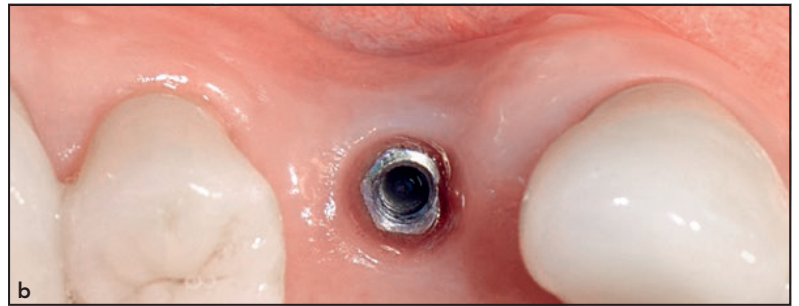
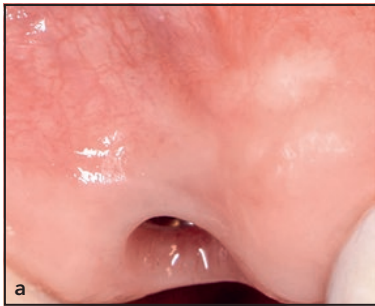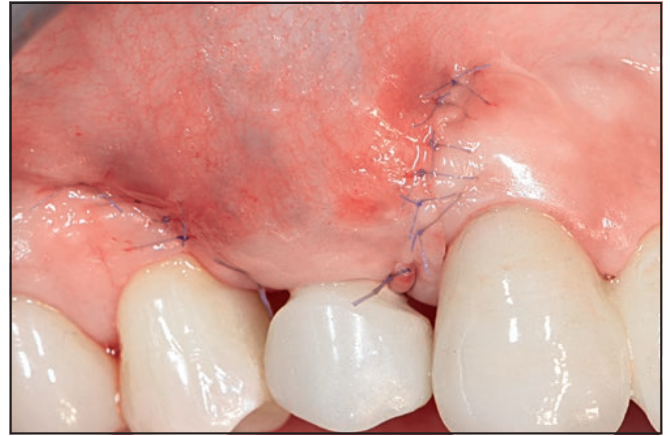


**Fig 2** (a) Buccal and (b) profile views at 2 months show the clinical situation after the removal of the existing implant crowns and the placement of a narrow provisional screw-retained crown to allow an increase in the interproximal space between the crown and the adjacent teeth.



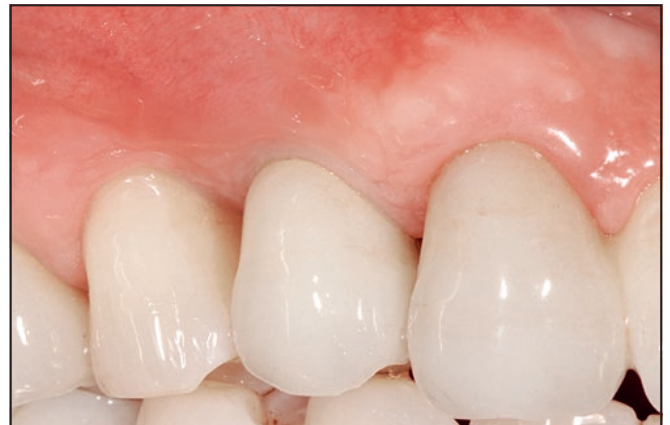**Fig 3** (a) Surgical procedure: After flap elevation, the matrix was positioned to cover the implant-crown interface and was apically and laterally secured at the base of each anatomical papilla with simple interrupted sutures to obtain complete stability and adaptation of the collagen matrix. (b) The anatomical papillae were deepithelialized in the vestibular and occlusal aspects (white arrows).

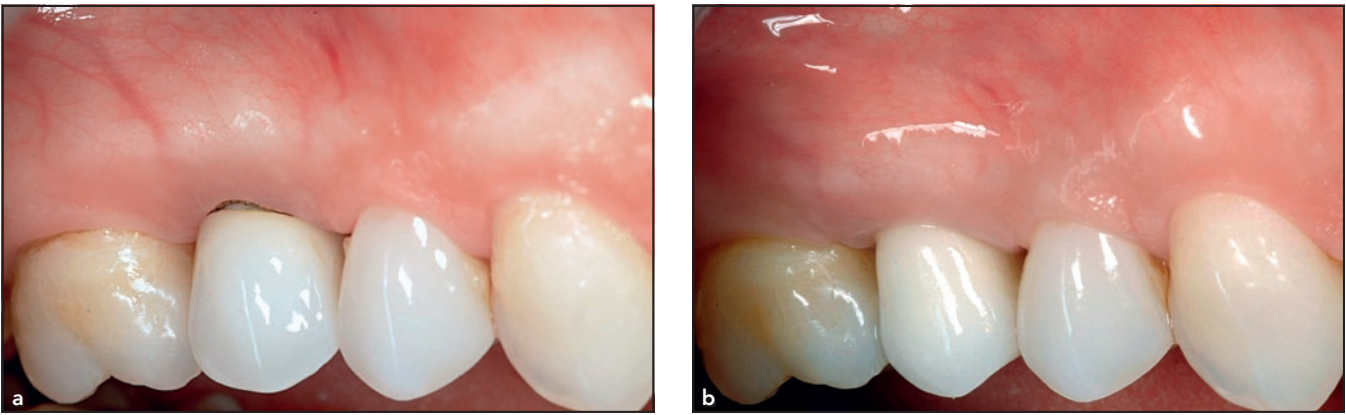
**Fig 4** The flap was repositioned, completely covering the matrix without tension, and was fixed with simple interrupted sutures along the vertical releasing incisions and with a coronal sling suture. The provisional crown was further reduced to avoid contact with the soft tissues.



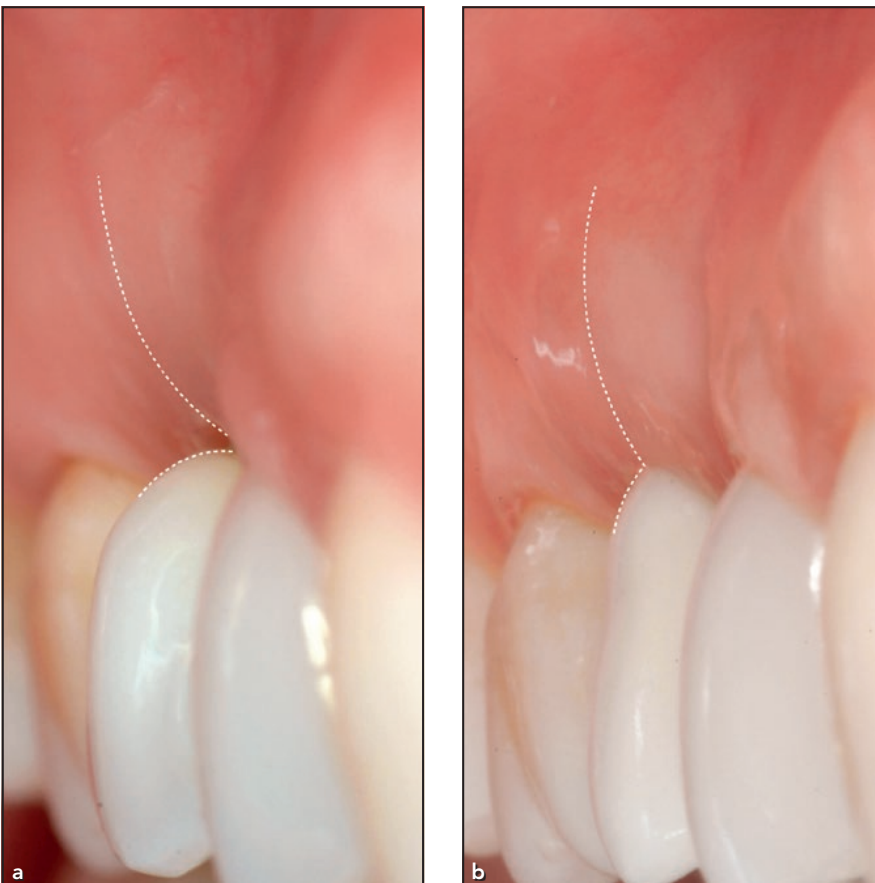**Fig 5** Comparison between (a) buccal and (b) occlusal situations at baseline and (c) buccal and (d) occlusal pictures at 6 months postsurgery.

**Fig 6** Buccal clinical view 1 year after final restoration.





**Fig 7** Buccal views of another patient (a) at baseline and (b) 1 year after final restoration.



**Fig 8** Profile view (a) at baseline and (b) 1 year after final restoration, showing the increase in soft tissue thickness and the correction of the emergence profile of the implant-supported restoration.

At baseline, the mean STT (STT-0) was  $1.03 \pm 0.21$  mm, the mean width of KT (KT-0) was  $1.7 \pm 0.48$  mm, and the mean PD (PD-0) was  $2.4 \pm 0.77$  mm.

Definitive implant-supported restorations were placed 6 months after surgery. Whenever possible, screw-retained crowns were made; conversely, in the case of definitive cemented restorations, temporary cement was used in order to allow the removal of the crown at the time of the final evaluation, which was performed 1 year after final restoration placement.

At the 1-year follow-up, STT-1 was  $2.23 \pm 1.89$  mm with a mean increase between baseline and 1 year of  $1.2 \pm 0.18$  mm; mean KTH-1 was  $2.35 \pm 0.47$  mm, showing a mean difference of  $0.65 \pm 0.41$  mm with respect to baseline. The changes in STT did not adversely affect PD values, yielding a PD-1 of  $1.8 \pm 0.67$  mm (with  $-0.6 \pm 0.70$  mm mean difference between baseline and 1 year). Figures 7 and 8 show the 1-year increase in buccal STT for a clinical case.

## Discussion

In ideal situations in the esthetic area, the rough implant surface should be placed 3 to 3.5 mm apical to the future gingival margin of the prosthetic crown (which should be at the same level and have the same scallop as the gingival margin of the homologous natural tooth). This area, which in a natural tooth corresponds to the suprabony component of the buccal root surface devoid of buccal bone and with only soft tissue covering the prosthetic components, is called the peri-implant transmucosal portion.

The results from the present study demonstrated that the proposed bilaminar technique combining CAF and a PADM was effective in the treatment of buccal soft tissue deficiencies around single dental implants, leading to a mean STT-1 of  $2.23 \pm 0.19$  mm at the level of transmucosal portion facially (mean increase in STT:  $1.2 \pm 0.18$  mm).

The successful mean STT increase outcomes achieved in this study were similar to those reported by two recent randomized clinical trials comparing the use of collagen matrices with the use of connective tissue grafts for soft tissue volume increase at implant sites,<sup>10,16</sup> which obtained an increase in STT ranging between 0.9 and 1.1 mm for sites treated with the matrices, and an STT gain ranging between 0.8 and 1.2 mm for sites treated with connective tissue grafts. It should be noted that comparable results were achieved even if different surgical flap approaches and different soft tissue substitutes were used in the

cited studies. However, their follow-up periods consisted only of 3 and 6 months.

The results obtained in terms of final STT are in accordance with the minimum 2 mm of mucosal thickness needed for the maintenance of stable bone levels and for masking the metallic transparency of the underlying implant-prosthetic components.<sup>4-7,25</sup> The biologic importance of these results is directly related to prevention of the damage inflicted by the inflammatory infiltrate induced by subgingival plaque or toothbrushing trauma; said infiltrate is known to irradiate for 1 to 2 mm.<sup>26</sup> On this basis, a minimum soft tissue thickness of 2 mm is recommended to prevent soft tissue dehiscence at implant-supported restorations.<sup>27</sup> At the end of this study, all sites complied with this threshold value, fulfilling both esthetic and biologic requirements for long-term stability.

Only one other clinical study has been published using the same PADM for peri-implant soft tissue augmentation,<sup>28</sup> but in said article, keratinized mucosa width was the primary outcome variable, the augmentation procedure was done along with implant uncovering, and the article failed to report volumetric buccolingual dimensional changes. Augmentation of keratinized gingiva was outside the scope of the present study, but it should be noted that KTH was not lost despite coronal advancement of the buccal tissues, and it remained stable (mean difference:  $0.65 \pm 0.41$  mm).

Even so, study trends point to the greater importance of adequate buccal STT over an arbitrary amount

of keratinized gingiva, whose absolute minimum requirements have yet to be defined.

The main limitations of this study include the small sample size and absence of a control group. The study evaluated the effects of CAF with PADM for buccal soft tissue augmentation on specifically selected cases: esthetic area, sites free of peri-implantitis, no initial probing indicating buccal implant exposure/dehiscence, and no interproximal attachment loss on neighboring teeth. Potential vertical soft tissue augmentation for soft tissue dehiscence coverage and specific bone level assessments were outside the scope of this study and therefore were not reported.

## Conclusions

Following adequate pre- and post-surgical restorative protocols, the studied PADM in combination with CAF was effective for buccal soft tissue augmentation, gaining an average of  $1.2 \pm 0.18$  mm at single implant sites in the esthetic area 1 year after final restoration placement. The use of the matrix along with the proposed surgical protocol provides conditions for attaining buccal soft tissue augmentation that is in compliance with esthetic-functional requirements at implant sites.

Further studies should be performed in order to assess long-term stability and its efficacy compared to connective tissue grafts.



## Acknowledgments

The authors declare that the present study was partly supported by Botiss, Berlin, Germany. Prosthodontic treatment was performed by Dr Mauro Fadda, Italy.

## References

- Jung RE, Al-Nawas B, Araujo M, et al. Group 1 ITI Consensus Report: The influence of implant length and design and medications on clinical and patient-reported outcomes. *Clin Oral Implants Res* 2018;29(suppl 16):s69–s77.
- Thoma DS, Naenni N, Figuero E, et al. Effects of soft tissue augmentation procedures on peri-implant health or disease: A systematic review and meta-analysis. *Clin Oral Implants Res* 2018;29(suppl 15):s32–s49.
- Giannobile WV, Jung RE, Schwarz F, Groups of the 2nd Osteology Foundation Consensus Meeting. Evidence-based knowledge on the aesthetics and maintenance of peri-implant soft tissues: Osteology Foundation Consensus Report Part 1—Effects of soft tissue augmentation procedures on the maintenance of peri-implant soft tissue health. *Clin Oral Implants Res* 2018;29(suppl 15):s7–s10.
- Jung RE, Sailer I, Hämmerle CH, Attin T, Schmidlin P. In vitro color changes of soft tissues caused by restorative materials. *Int J Periodontics Restorative Dent* 2007;27:251–257.
- Ioannidis A, Cathomen E, Jung RE, Fehmer V, Hüsler J, Thoma DS. Discoloration of the mucosa caused by different restorative materials—A spectrophotometric in vitro study. *Clin Oral Implants Res* 2017;28:1133–1138.
- Van Eekeren P, van Elsland P, Tahmaseb A, Wismeijer D. The influence of initial mucosal thickness on crestal bone change in similar macrogeometrical implants: A prospective randomized clinical trial. *Clin Oral Implants Res* 2017;28:214–218.
- Bassetti RG, Stähli A, Bassetti MA, Sculean A. Soft tissue augmentation procedures at second-stage surgery: A systematic review. *Clin Oral Investig* 2016;20:1369–1387.
- Thoma DS, Buranawat B, Hämmerle CH, Held U, Jung RE. Efficacy of soft tissue augmentation around dental implants and in partially edentulous areas: A systematic review. *J Clin Periodontol* 2014;41(suppl 15):s77–s91.
- Bassetti RG, Stähli A, Bassetti MA, Sculean A. Soft tissue augmentation around osseointegrated and uncovered dental implants: A systematic review. *Clin Oral Investig* 2017;21:53–70.
- Cairo F, Barbato L, Tonelli P, Batalocco G, Pagavino G, Nieri M. Xenogeneic collagen matrix versus connective tissue graft for buccal soft tissue augmentation at implant site. A randomized, controlled clinical trial. *J Clin Periodontol* 2017;44:769–776.
- Zucchelli G, Mele M, Stefanini M, et al. Patient morbidity and root coverage outcome after subepithelial connective tissue and de-epithelialized grafts: A comparative randomized-controlled clinical trial. *J Clin Periodontol* 2010;37:728–738.
- Lorenzo R, García V, Orsini M, Martin C, Sanz M. Clinical efficacy of a xenogeneic collagen matrix in augmenting keratinized mucosa around implants: A randomized controlled prospective clinical trial. *Clin Oral Implants Res* 2012;23:316–324.
- Fickl S, Fischer KR, Jockel-Schneider Y, Stappert CF, Schlagenhauf U, Kerschull M. Early wound healing and patient morbidity after single-incision vs. trap-door graft harvesting from the palate—A clinical study. *Clin Oral Investig* 2014;18:2213–2219.
- Kasaj A. Gingival recession coverage: Do we still need autogenous grafts? *Quintessence Int* 2016;47:775–783.
- Song YW, Kim S, Waller T, et al. Soft tissue substitutes to increase gingival thickness: Histologic and volumetric analyses in dogs. *J Clin Periodontol* 2019;46:96–104.
- Thoma DS, Zeltner M, Hilbe M, Hämmerle CH, Hüsler J, Jung RE. Randomized controlled clinical study evaluating effectiveness and safety of a volume-stable collagen matrix compared to autogenous connective tissue grafts for soft tissue augmentation at implant sites. *J Clin Periodontol* 2016;43:874–885.
- Levin BP, Chu SJ. Changes in peri-implant soft tissue thickness with bone grafting and dermis allograft: A case series of 15 consecutive patients. *Int J Periodontics Restorative Dent* 2018;38:719–727.
- Naenni N, Bienz SP, Benic GI, Jung RE, Hämmerle CHF, Thoma DS. Volumetric and linear changes at dental implants following grafting with volume-stable three-dimensional collagen matrices or autogenous connective tissue grafts: 6-month data. *Clin Oral Investig* 2018;22:1185–1195.
- Zucchelli G, Tavelli L, Stefanini M, et al. Classification of facial peri-implant soft tissue dehiscences/deficiencies at single implant sites in the esthetic zone. *J Periodontol* 2019;90:1116–1124.
- Paolantonio M, Dolci M, Esposito P, et al. Subpedicle acellular dermal matrix graft and autogenous connective tissue graft in the treatment of gingival recessions: A comparative 1-year clinical study. *J Periodontol* 2002;73:1299–1307.
- Da Silva RC, Joly JC, de Lima AF, Tatakis DN. Root coverage using the coronally positioned flap with or without a subepithelial connective tissue graft. *J Periodontol* 2004;75:413–419.
- Joly JC, Carvalho AM, da Silva RC, Ciotti DL, Cury PR. Root coverage in isolated gingival recessions using autograft versus allograft: A pilot study. *J Periodontol* 2007;78:1017–1022.
- Zucchelli G, Amore C, Sforza NM, Montebugnoli L, De Sanctis M. Bilaminar techniques for the treatment of recession-type defects. A comparative clinical study. *J Clin Periodontol* 2003;30:862–870.
- Zucchelli G, Mazzotti C, Mounssif I, Mele M, Stefanini M, Montebugnoli L. A novel surgical-prosthetic approach for soft tissue dehiscence coverage around single implant. *Clin Oral Implants Res* 2013;24:957–962.
- Van Brakel R, Noordmans HJ, Frenken J, de Roode R, de Wit GC, Cune MS. The effect of zirconia and titanium implant abutments on light reflection of the supporting soft tissues. *Clin Oral Implants Res* 2011;22:1172–1178.
- Waerhaug J. Subgingival plaque and loss of attachment in periodontitis as observed in autopsy material. *J Periodontol* 1976;47:636–642.
- Mazzotti C, Stefanini M, Felice P, Bentivogli V, Mounssif I, Zucchelli G. Soft-tissue dehiscence coverage at peri-implant sites. *Periodontol* 2000 2018;77:256–272.
- Papi P, Pompa G. The use of a novel porcine derived acellular dermal matrix (Mucoderm) in peri-implant soft tissue augmentation: Preliminary results of a prospective pilot cohort study. *BioMed Res Int* 2018;2018:6406051.